



Owner's Copy

**PennHIP Report**

Referring Veterinarian: Dr Mike Ferrera Email: squawpeakanimalhospital@yahoo.com	Clinic Name: Squaw Peak Animal Hospital Clinic Address: 3165 East Lincoln Drive Suite 115 Phoenix, AZ 85016 Phone: (602) 553-8855 Fax: (602) 553-0188
---	---

**Patient Information**

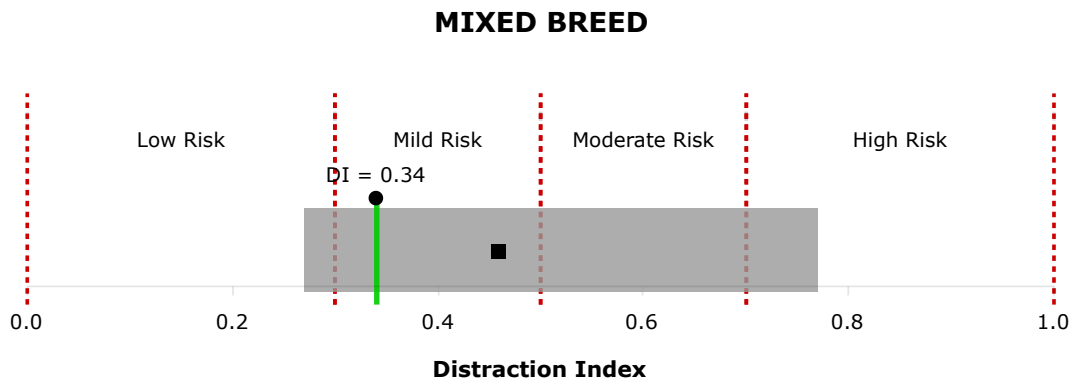
Client: Palmer, Shannon Patient Name: Aphrodite Reg. Name: N/A PennHIP Num: 180538 Species: Canine Date of Birth: 10 Feb 2022 Sex: Female Date of Study: 19 Oct 2022 Date of Report: 20 Oct 2022	Tattoo Num: N/A Patient ID: 9288539255 Aphroite Registration Num: N/A Microchip Num: 900235000134267 Breed: MIXED BREED Age: 8 months Weight: 17.4 lbs/7.9 kgs Date Submitted: 19 Oct 2022
--	---

**Findings**

Distraction Index (DI): Right DI = 0.28, Left DI = 0.34.  
 Osteoarthritis (OA): **No radiographic evidence of OA for either hip.**  
 Cavitation/Other Findings: No cavitation present.

**Interpretation**

Distraction Index (DI): The laxity ranking is based on the hip with the greater laxity (larger DI). In this case the DI used is 0.34.  
 OA Risk Category: The DI is between 0.31 and 0.49. This patient is at mild risk for hip OA.  
 Distraction Index Chart:



**BREED STATISTICS:** This interpretation is based on a cross-section of 11813 canine patients of the MIXED BREED breed in the AIS PennHIP database. The gray strip represents the central 90% range of DIs (0.27 - 0.77) for the breed. The breed average DI is 0.46 (solid square). The patient DI is the solid circle (0.34).

**SUMMARY:** The degree of laxity (DI = 0.34) falls within the central 90% range of DIs for the breed. This amount of hip laxity places the hip at a mild risk to develop hip OA. **No radiographic evidence of OA for either hip.**