

## PennHIP Report

Referring Veterinarian: Dr Mike Ferrara	Clinic Name: Squaw Peak Animal Hospital
Email: squawpeakanimalhospital@yahoo.com	Clinic Address: 3165 East Lincoln Drive Suite 115
	Phoenix, AZ 85016
	Phone: (602) 553-8855
	Fax: (602) 553-0188

## Patient Information

Client: Palmer, Shannon	Tattoo Num: N/A
Patient Name: Gunner	Patient ID: 9288539255 Gunner
Reg. Name: Villa Pine Gunstock's Gunner	Registration Num: PR25531801
PennHIP Num: 180542	Microchip Num: 992001001202791
Species: Canine	Breed: STANDARD POODLE
Date of Birth: 15 Apr 2022	Age: 6 months
Sex: Male	Weight: 18.2 lbs/8.3 kgs
Date of Study: 19 Oct 2022	Date Submitted: 19 Oct 2022
Date of Report: 20 Oct 2022	

## Findings

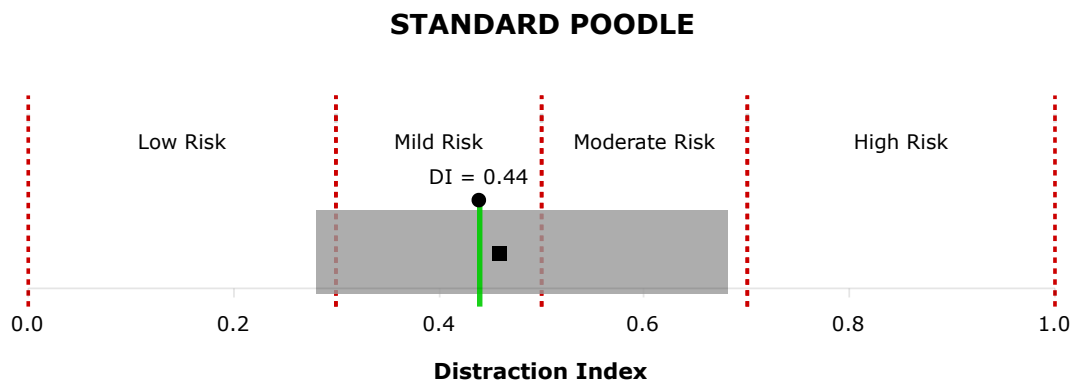
Distraction Index (DI): Right DI = 0.44, Left DI = 0.36.  
 Osteoarthritis (OA): **No radiographic evidence of OA for either hip.**  
 Cavitation/Other Findings: No cavitation present.

## Interpretation

Distraction Index (DI): The laxity ranking is based on the hip with the greater laxity (larger DI). In this case the DI used is 0.44.

OA Risk Category: The DI is between 0.31 and 0.49. This patient is at mild risk for hip OA.

Distraction Index Chart:



**BREED STATISTICS:** This interpretation is based on a cross-section of 5784 canine patients of the STANDARD POODLE breed in the AIS PennHIP database. The gray strip represents the central 90% range of DIs (0.28 - 0.68) for the breed. The breed average DI is 0.46 (solid square). The patient DI is the solid circle (0.44).

**SUMMARY:** The degree of laxity (DI = 0.44) falls within the central 90% range of DIs for the breed. This amount of hip laxity places the hip at a mild risk to develop hip OA. **No radiographic evidence of OA for either hip.**